Noninvasive Diagnosis and Staging of Liver Disease

Naveen Gara, MD

Texas Liver Institute

UT Health San Antonio School of Medicine

Outline

- Brief overview of the anatomy of liver
- Liver-related lab tests
- Chronic liver disease progression
- Estimation of liver fibrosis
- Non-invasive means of liver fibrosis evaluation
- Summary

Texas Liver Institute
UT Health San Antonio School of Medicine

Liver

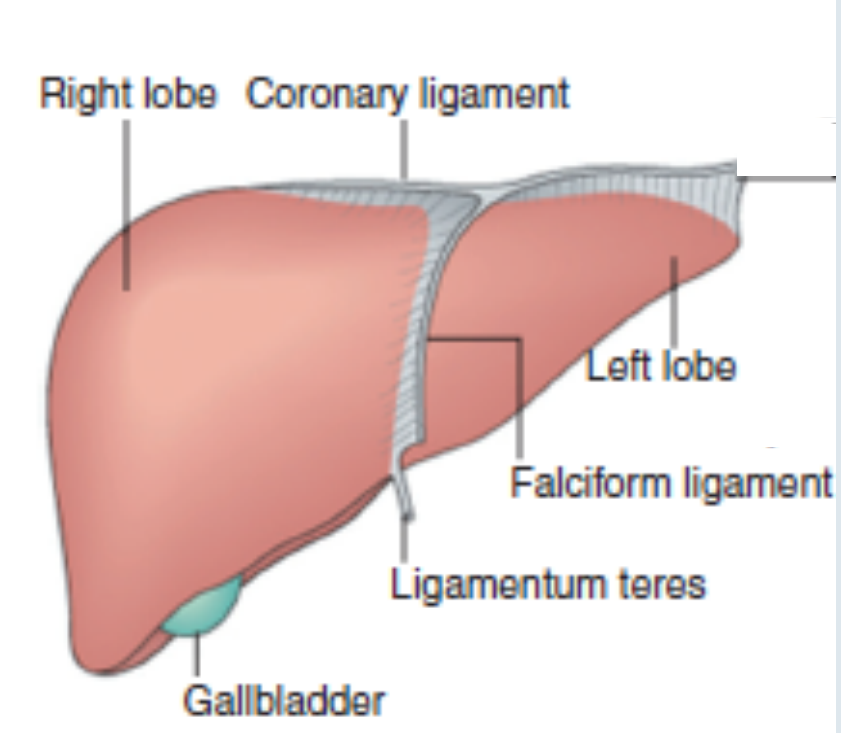

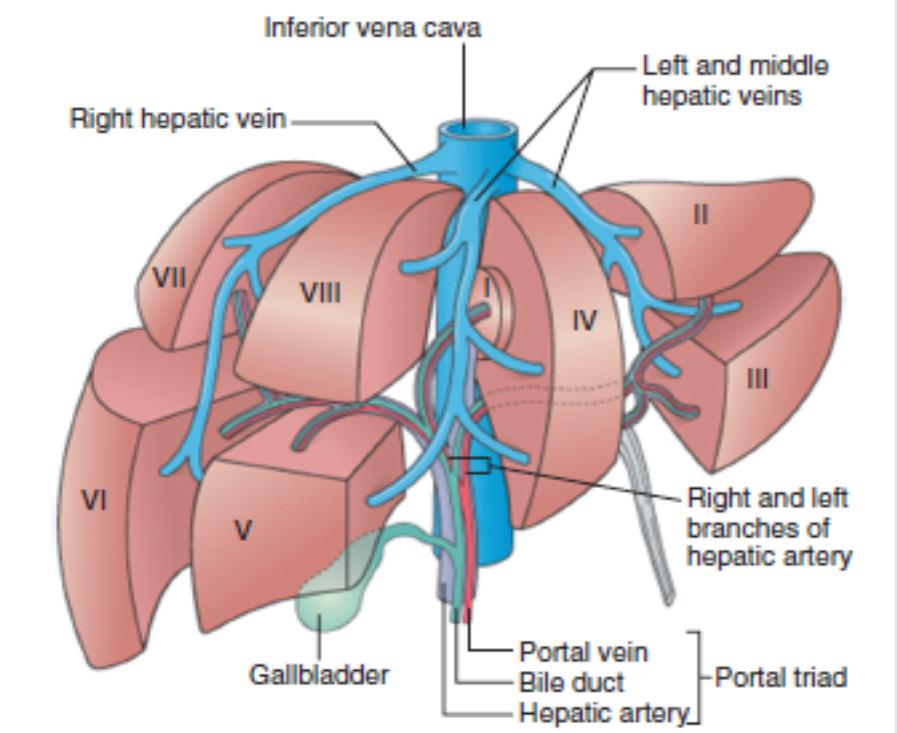

Moore KL, Dalley AF. Clinically oriented anatomy, 4th edition: Philadelphia: Lippincott Williams & Wilkins, 1999: 268

Texas Liver Institute

UT Health San Antonio School of Medicine

Liver-related Labs

- Aspartate Aminotransferase (AST)
- Alanine Aminotransferase (ALT)
- Alkaline Phosphatase
- Gamma Glutamyl Transpeptidase (GGT)
- Bilirubin
- Albumin
- Prothrombin time (PT/INR)
- Platelet count

Texas Liver Institute
UT Health San Antonio School of Medicine

Causes of Chronic Liver Disease

- Chronic Viral Hepatitis (B,C)
- Alcoholic Liver Disease
- Nonalcoholic Fatty Liver Disease
- Autoimmune Liver Diseases (Autoimmune Hepatitis, Primary Biliary Cholangitis, Primary Sclerosing Cholangitis)
- Inherited Metabolic Defects (Hemochromatosis, Wilson Disease, Alpha-1-antitrypsin deficiency, etc.)
- Other

Texas Liver Institute
UT Health San Antonio School of Medicine

Progression of Chronic Liver Disease

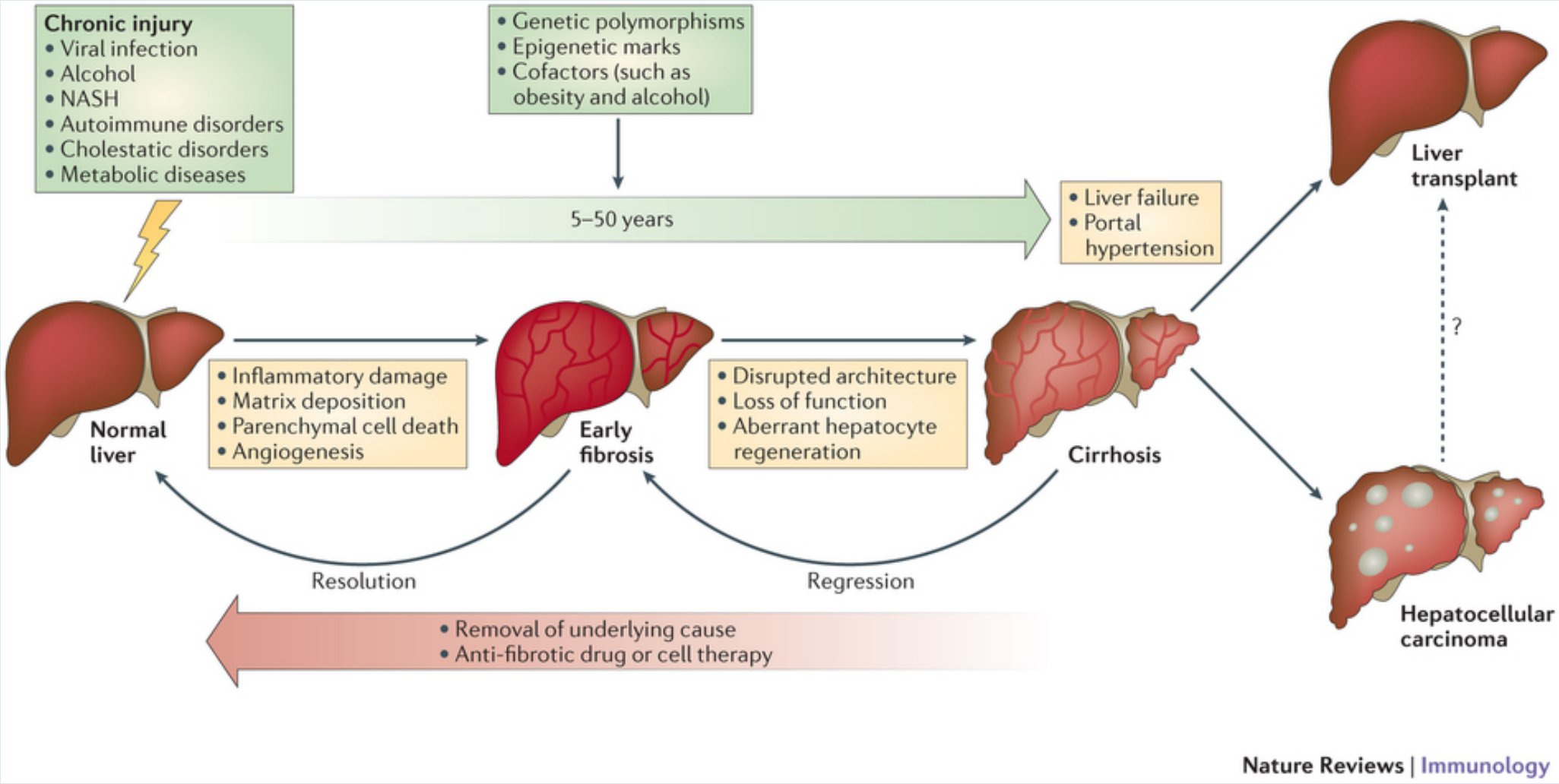

Pellicoro A, Ramachandran P et al; Nature Reviews Immunology 14; 181-194 (2014)

Texas Liver Institute

UT Health San Antonio School of Medicine

Staging of Liver Fibrosis

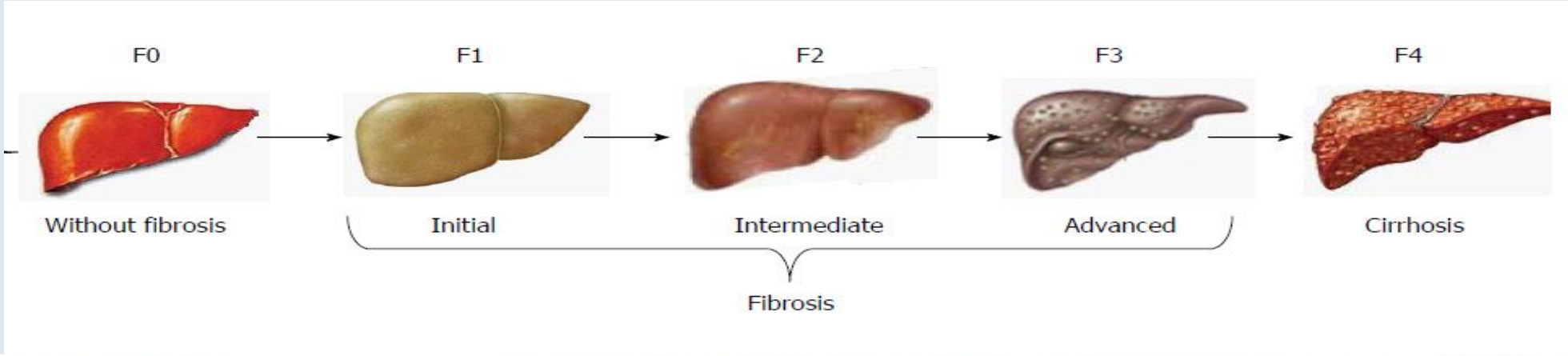

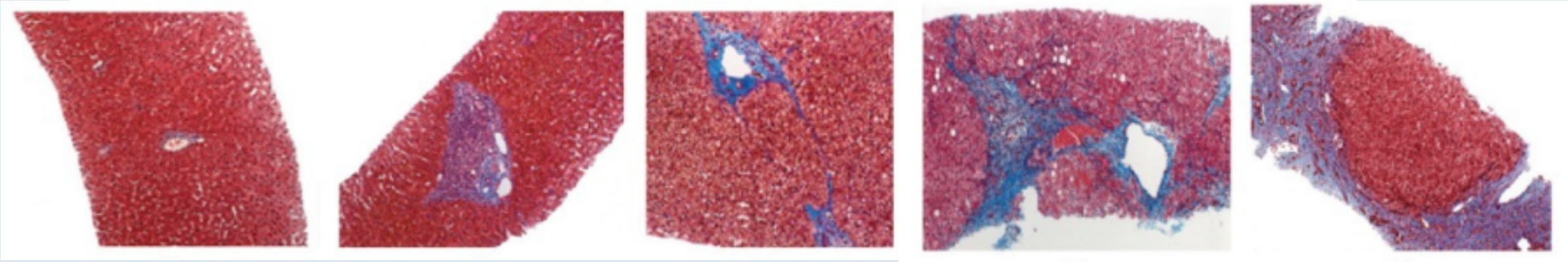

Faria S, Ganesan K, et al. MR imaging of liver fibrosis: current state of art; 2009; Oct; 29(6); 1615-35

Texas Liver Institute

UT Health San Antonio School of Medicine

Liver Biopsy

- Percutaneous
- Transjugular
- Laparoscopic
- EUS-guided

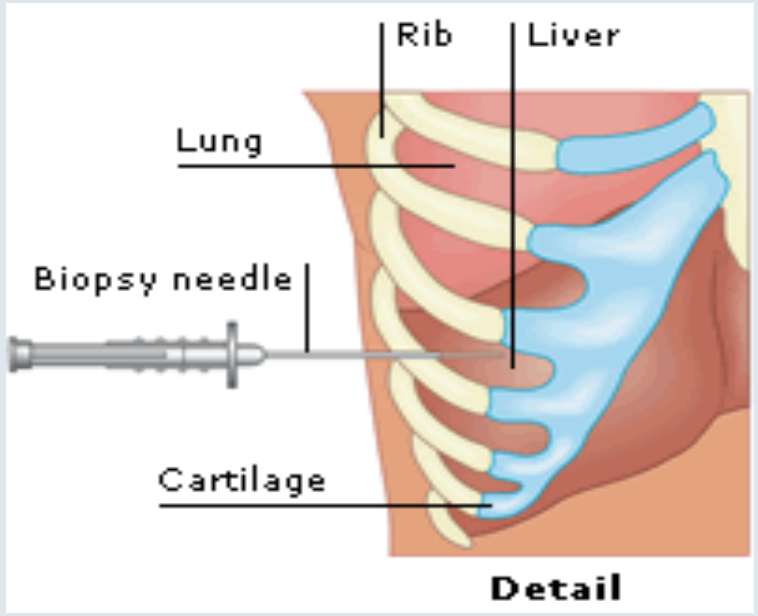

http://www.mayoclinic.org/tests-procedures/liver-biopsy/multimedia/liver-biopsy/img-20007146

Texas Liver Institute

UT Health San Antonio School of Medicine

Liver Biopsy

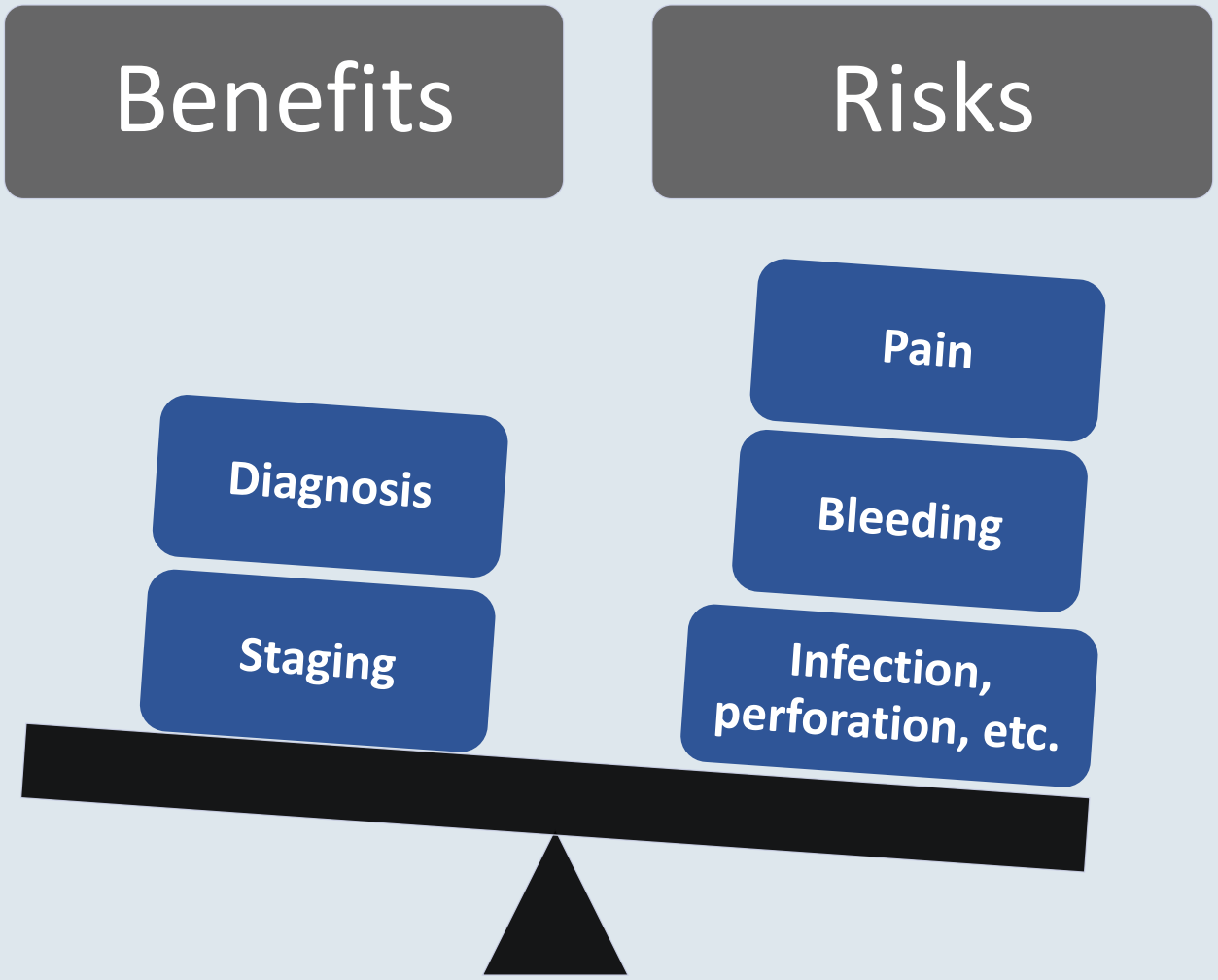

Pitfalls:

1. Sampling error
2. Subjective bias
3. Impracticability in obtaining serial biopsies

Texas Liver Institute

UT Health San Antonio School of Medicine

Noninvasive Assessment of Liver Fibrosis

Serologic tools:

- AST/ALT ratio
- AST to Platelet ratio index (APRI)
- FIB-4
- Forns index
- FibroSure
- FibroScore
- FibroSpect
- FibroMeter
- ELF score

Imaging tools:

- Traditional modalities (Ultrasound, CT, MRI)
- Newer techniques (Transient Elastography, Acoustic Radiation Force Impulse Imaging & Magnetic Resonance Elastography)

Texas Liver Institute

UT Health San Antonio School of Medicine

APRI

$$\text{APRI} = \frac{\dfrac{\text{AST Level}}{\text{AST (Upper Limit of Normal)}}}{\text{Platelet Count } (10^9/\text{L})} \times 100$$

Higher APRI score predictive of advanced fibrosis
APRI<1 = no/mild fibrosis; APRI>2=cirrhosis

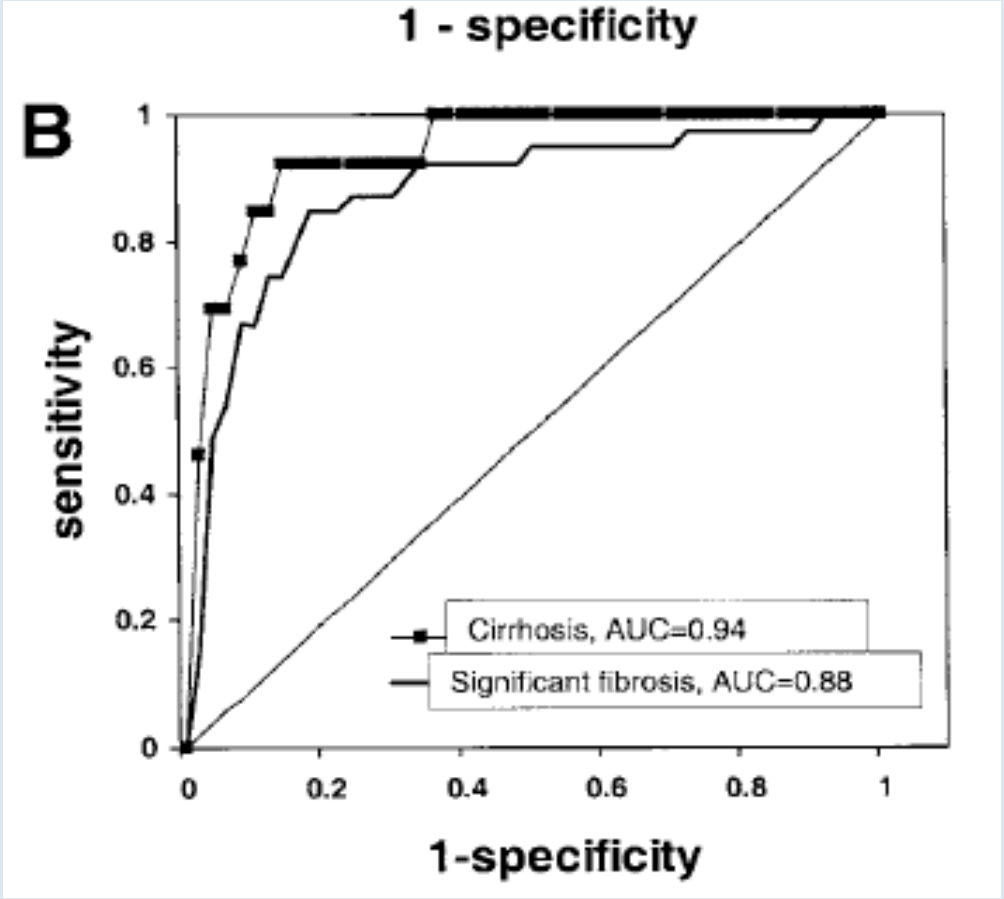

Wai CT, Greenson JK, et al. A simple noninvasive index can predict both cirrhosis and advanced fibrosis in chronic hepatitis C; *Hepatology*; 2003; Aug; 38(2):518-26

Texas Liver Institute

UT Health San Antonio School of Medicine

Serologic Tools for Fibrosis Assessment

$$\text{FIB-4} = \frac{\text{Age (years)} \times \text{AST (U/L)}}{\text{Platelet Count } (10^9/\text{L}) \times \sqrt{\text{ALT (U/L)}}}$$

APRI<1 = no/mild fibrosis; APRI>2=cirrhosis

Vallet-Pichard A, et al. FIB-4: an inexpensive and accurate marker of fibrosis. *Hepatology* 2007; 46; 32-6

$$\text{FibroIndex} = \begin{array}{l} 1.738 - 0.064 \times \text{platelet count } (10^4/\text{mm}^3) \\ + \\ 0.005 \times \text{AST (IU/L)} \\ + \\ 0.463 \times \text{gamma globulin (g/dL)} \end{array}$$

Koda M et al. Fibroindex, a practical index for predicting significant fibrosis in pts with chronic hep C. *Hepatology*; 2007; 45; 297-306

Texas Liver Institute

UT Health San Antonio School of Medicine

Cross-sectional Imaging

Ultrasound: heterogeneous texture

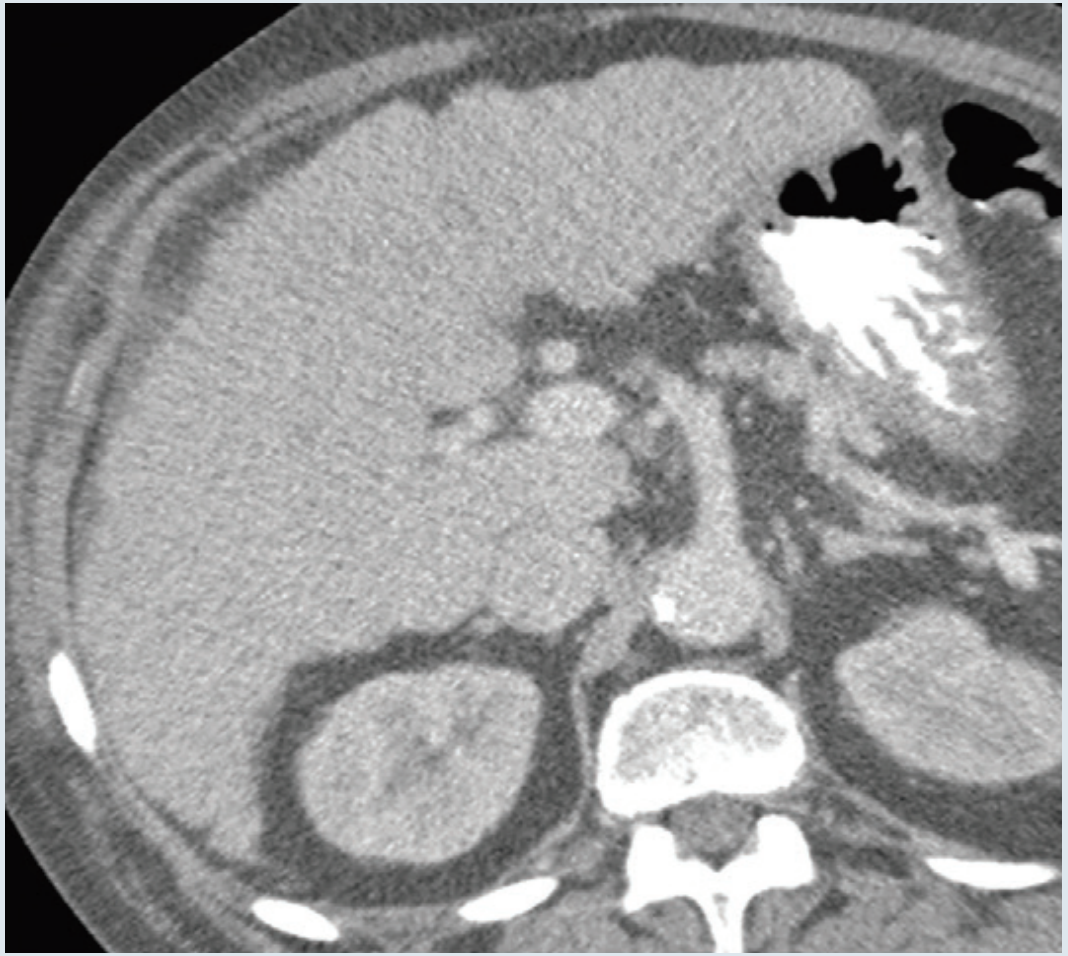

CT: nodular liver contour

Babu SA, et al. Elastography in chronic liver disease. Radiographics 2016

Texas Liver Institute

UT Health San Antonio School of Medicine

Cross-sectional Imaging

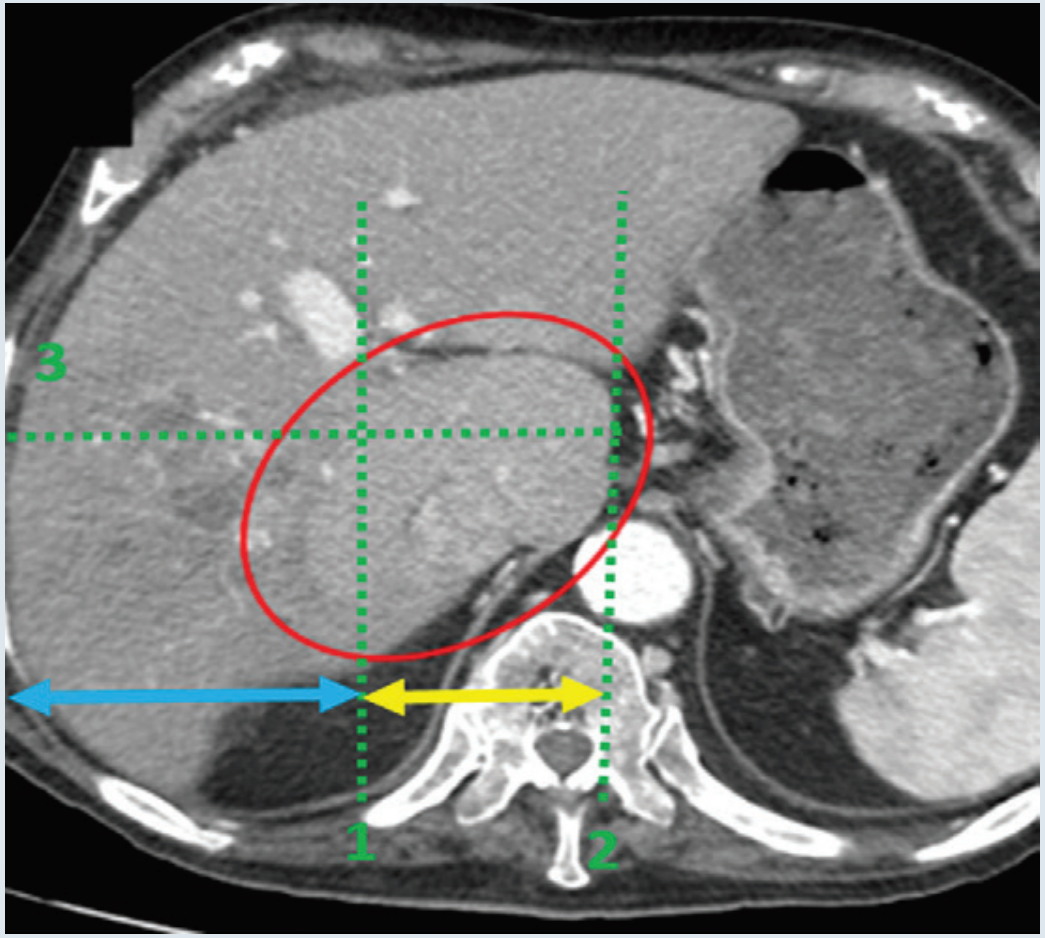

CT: Caudate lobe hypertrophy

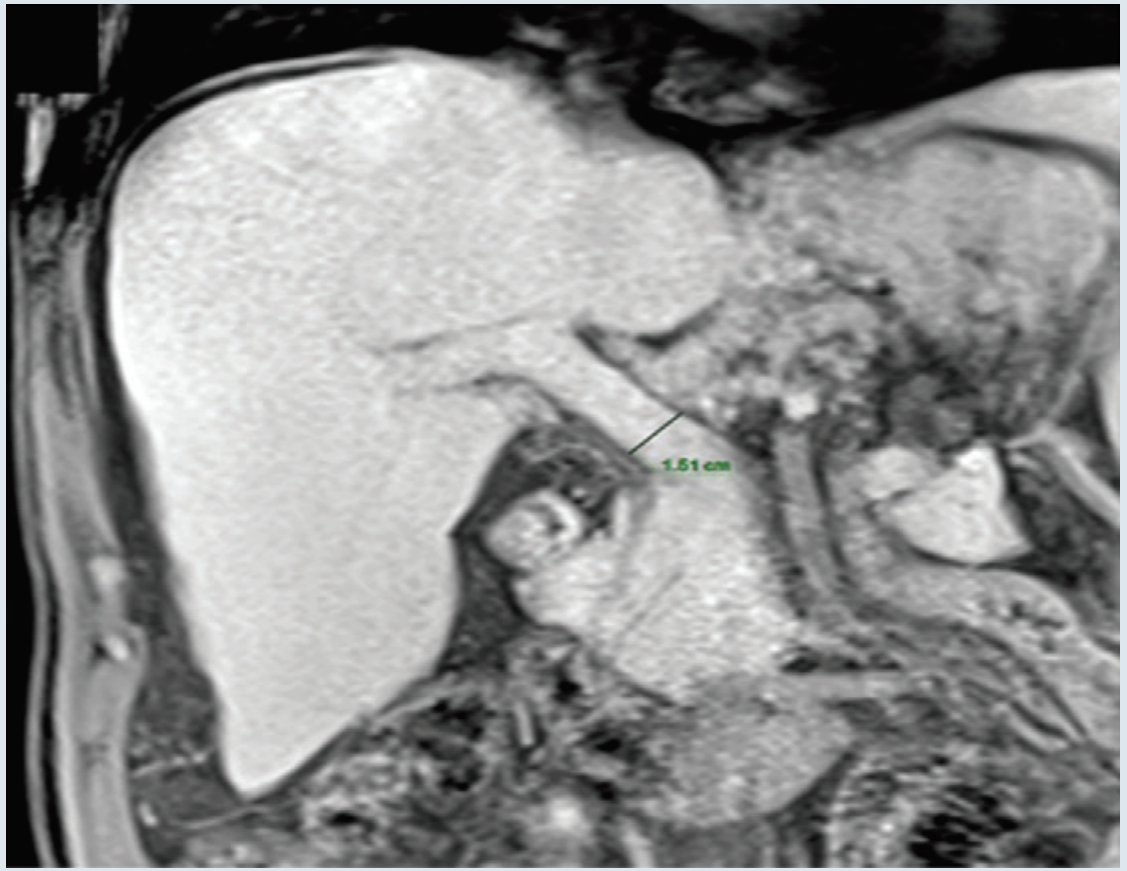

MRI: Dilated portal vein

Babu SA, Wells M, et al. Elastography in chronic liver disease: Modalities, techniques, limitations and future directions. Radiographics; 2016; 36; 1987-2006

Texas Liver Institute

UT Health San Antonio School of Medicine

Cross-sectional Imaging

Pitfalls:

- Lack of objectivity
- Inability to diagnose lesser degrees of fibrosis
- Even cirrhosis can be missed when gross changes in liver are not evident on imaging
- Subtle signs of cirrhosis have low inter-reader agreement

Texas Liver Institute
UT Health San Antonio School of Medicine

Transient Elastography

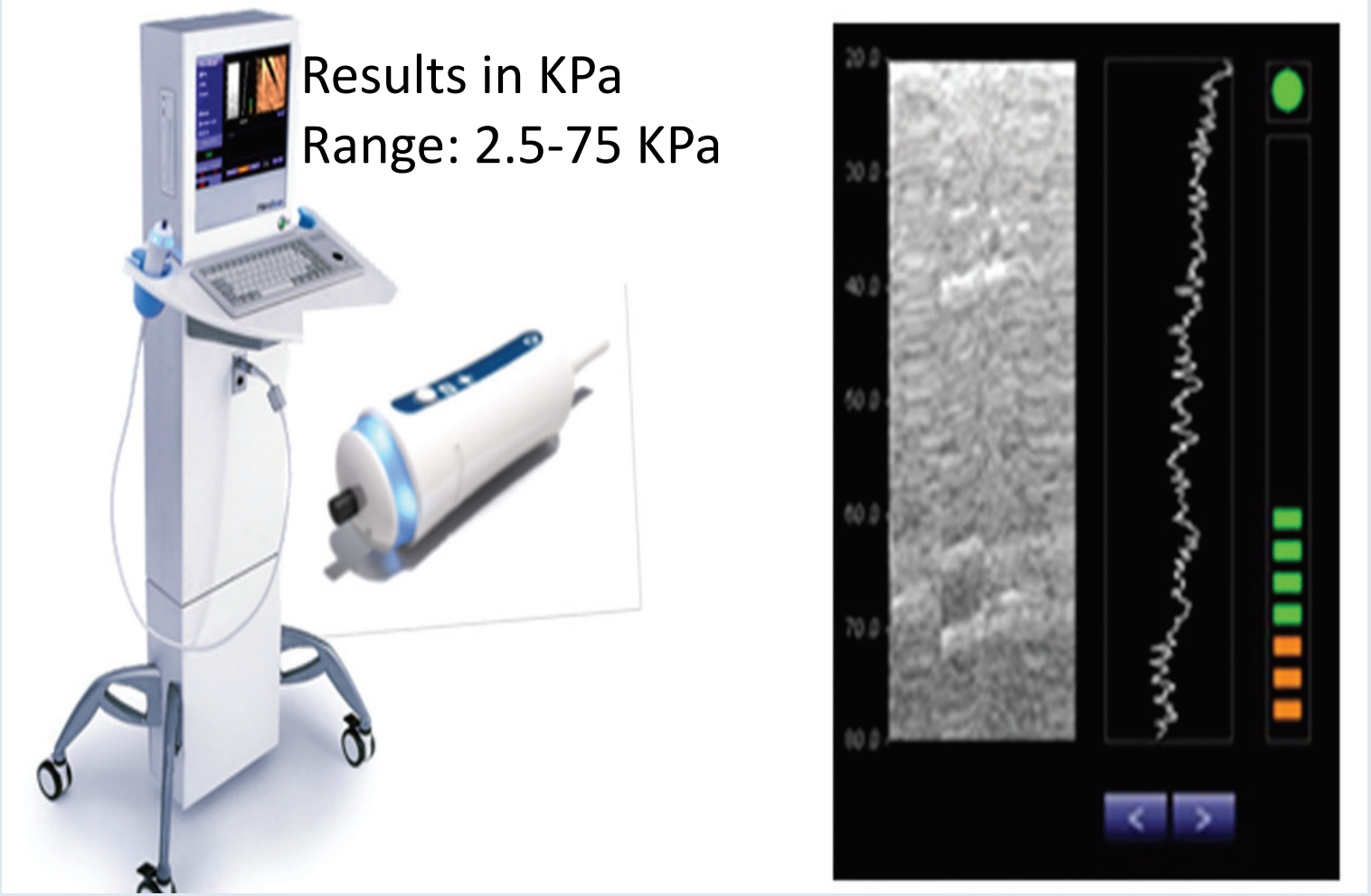

Tapper EB, Afdhal NH. Noninvasive assessment of disease progression. Zakim & Boyer's Textbook of Hepatology; 6th edition

Texas Liver Institute

UT Health San Antonio School of Medicine

Transient Elastography

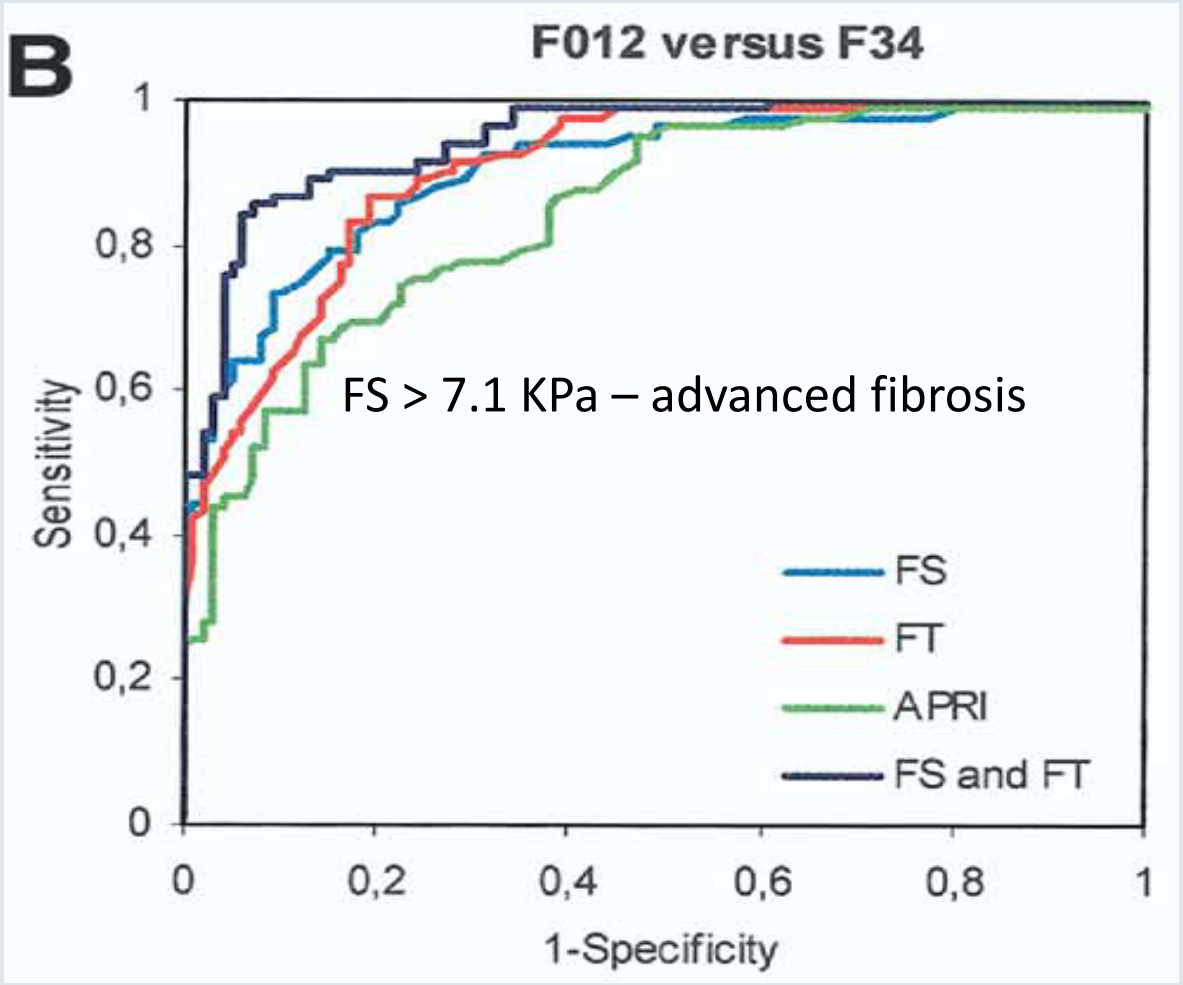

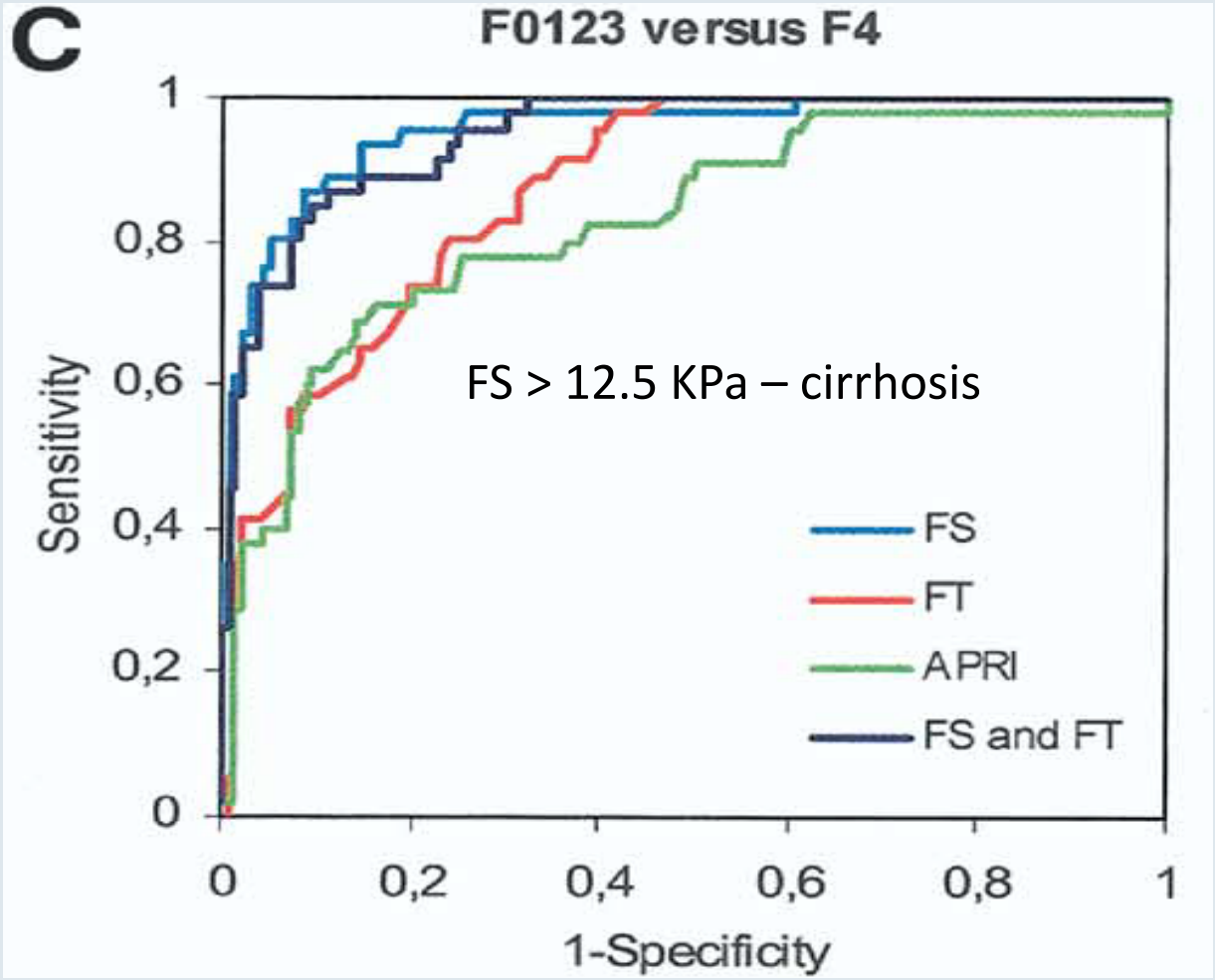

Castera L, Vergniol J, et al. Prospective comparison of transient elastography, Fibrotest, APRI & liver biopsy for the assessment of fibrosis in chronic hepatitis C. *Gastro*. 2005. Feb, 128 (2): 343-50

Texas Liver Institute

UT Health San Antonio School of Medicine

Transient Elastography

Pitfalls:

- Failure to obtain a valid result (obesity, narrow intercostal spaces, etc.)
- Can be spuriously high during a hepatitis flare
- On the contrary, Transient Elastography can also help diagnose cirrhosis in patients under-staged by biopsy

Gara N, Zhao X, et al. Discordance among transient elastography, APRI and histologic assessment of liver fibrosis in patients with chronic hepatitis C; *CGH*. 2013; 11(3); 303-8.

Texas Liver Institute
UT Health San Antonio School of Medicine

Magnetic Resonance Elastography (MRE)

- 3-dimensional imaging
- Potential to assess the stiffness of entire liver
- High technical success in obese & NASH patients as well
- Results range from 0.5 to 10 KPa

- Not available widely
- Expensive
- Requires trained radiologists

Texas Liver Institute
UT Health San Antonio School of Medicine

Magnetic Resonance Elastography (MRE)

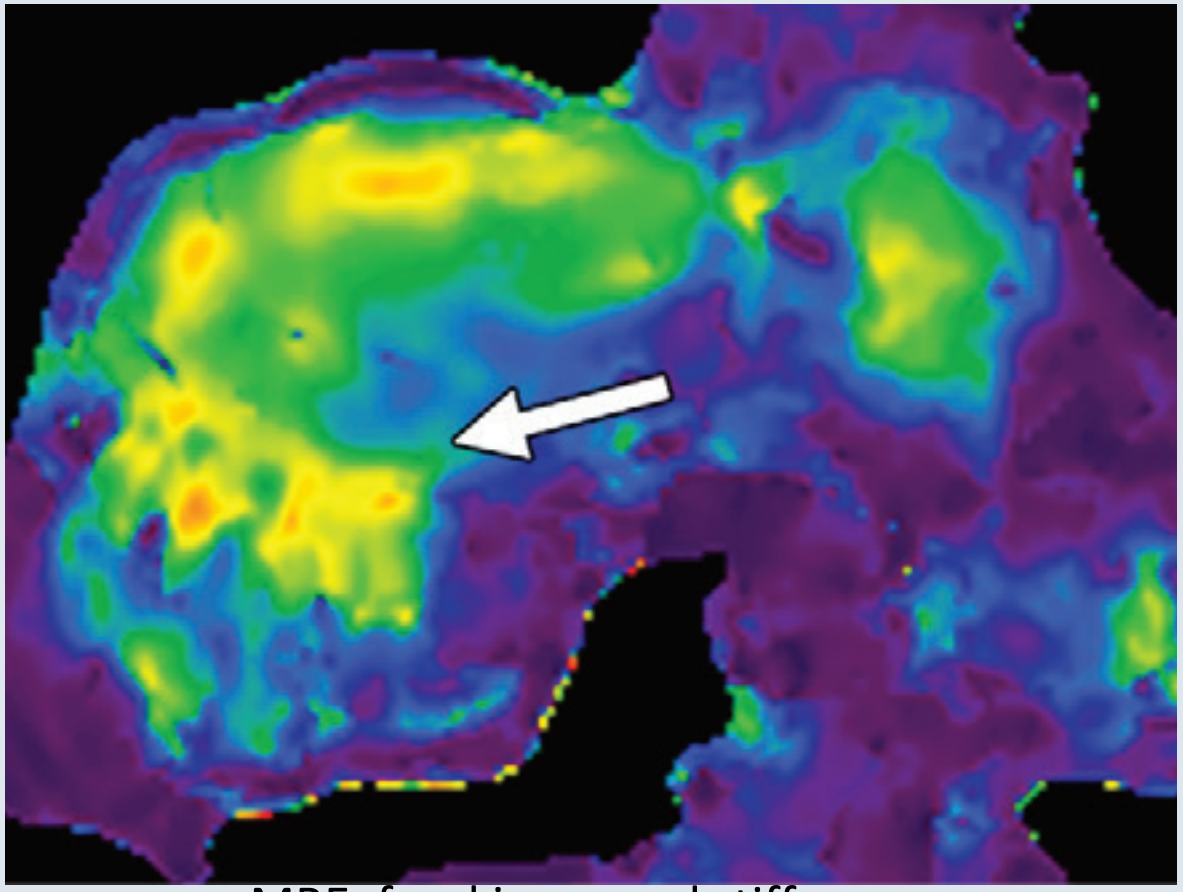

MRE: focal increased stiffness

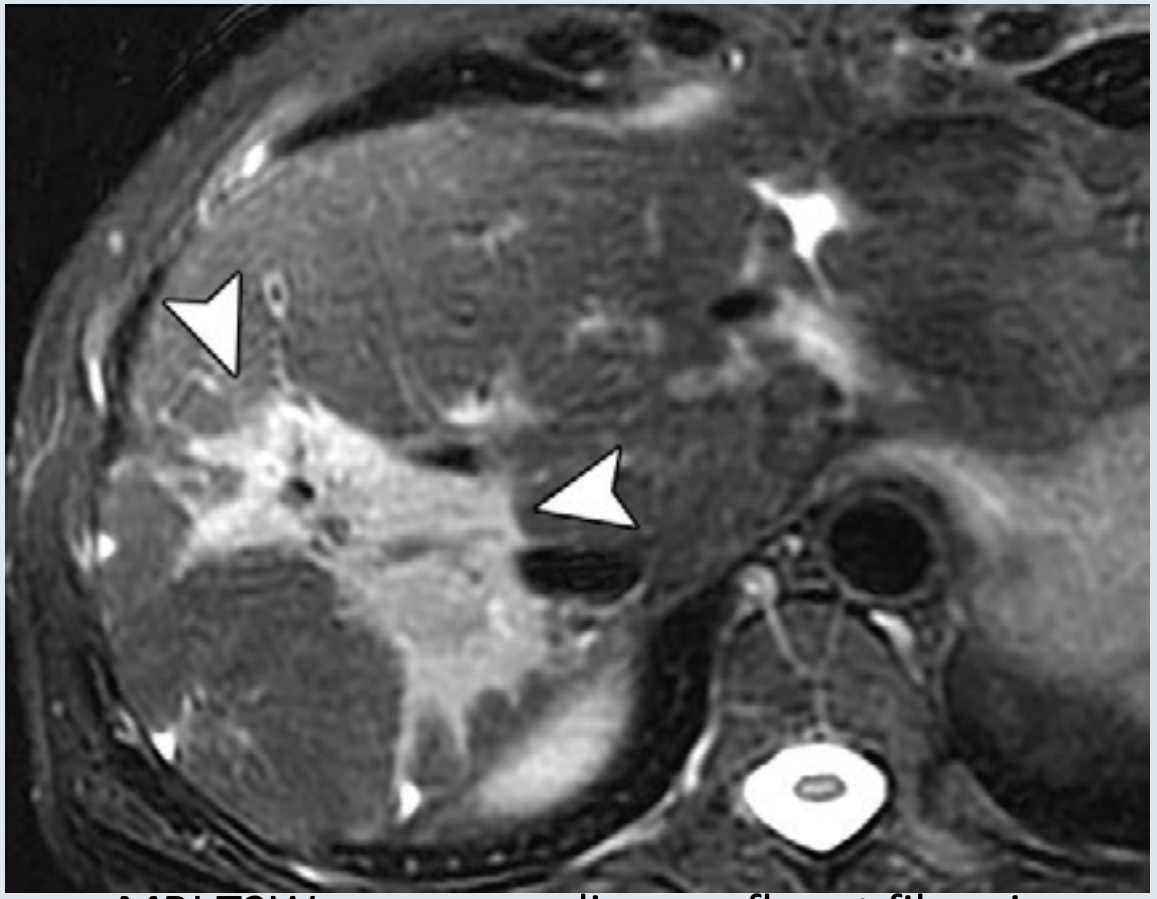

MRI T2W: corresponding confluent fibrosis

Babu SA, Wells M, et al. Elastography in chronic liver disease: Modalities, techniques, limitations and future directions. Radiographics; 2016; 36; 1987-2006

Texas Liver Institute

UT Health San Antonio School of Medicine

Summary

- Chronic liver disease from varied causes can lead to liver fibrosis
- Liver biopsy is considered the gold standard for fibrosis assessment
- Noninvasive tools have been proven to be reliable in differentiating between advanced and non-advanced fibrosis
- APRI is a simple index based on routine lab tests that can accurately diagnose cirrhosis and advanced fibrosis
- Elastography of the liver provides objective estimates of liver fibrosis using either ultrasound or MR techniques

Texas Liver Institute
UT Health San Antonio School of Medicine